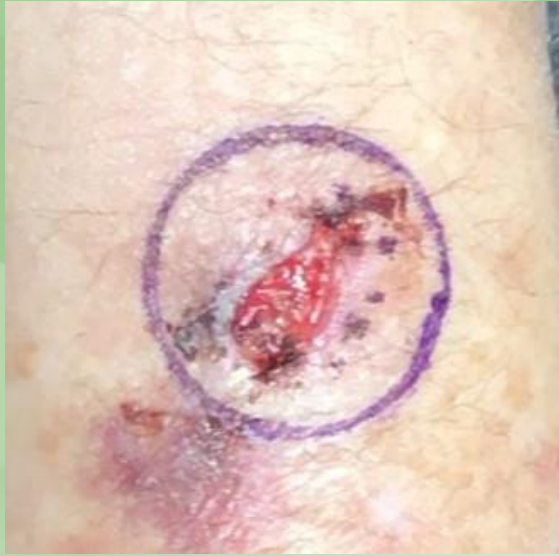

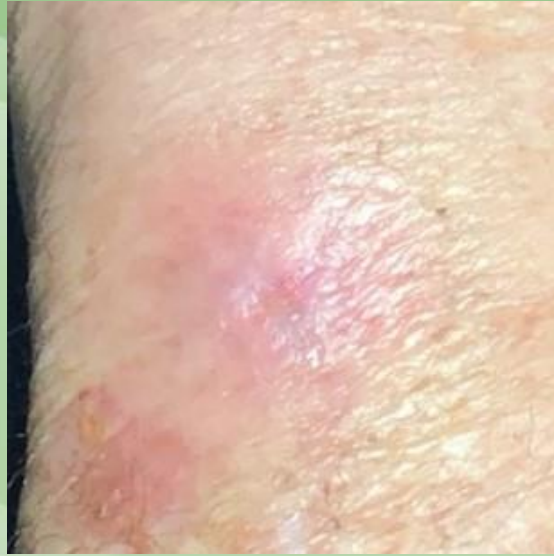Before and After Series

Before and after pictures with ultrasound images

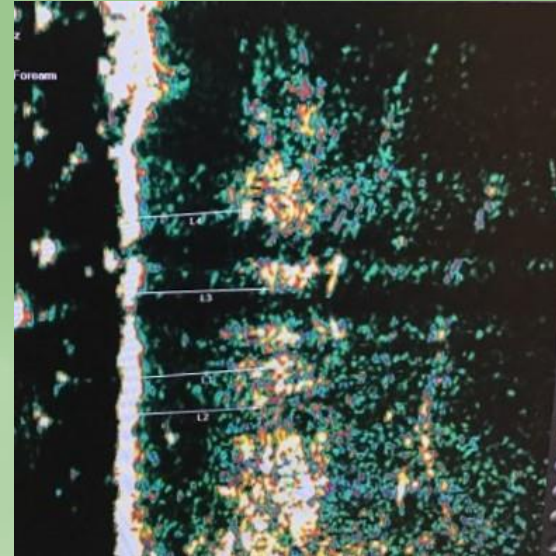
Arm



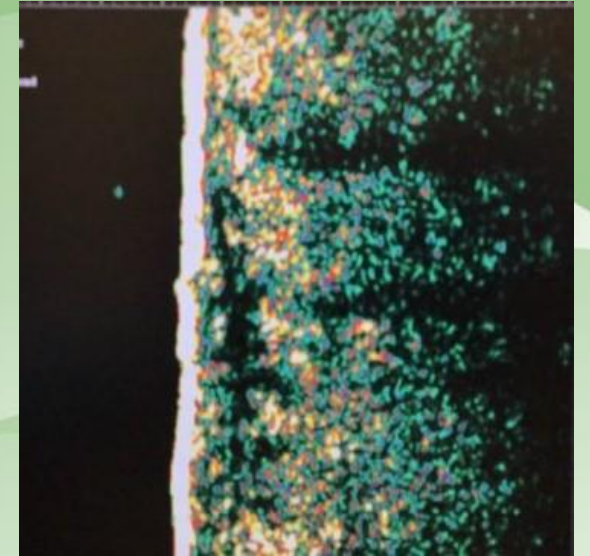
Before



After

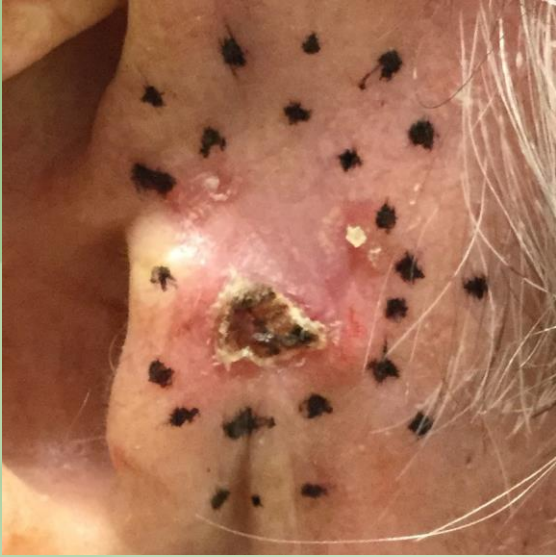

Before

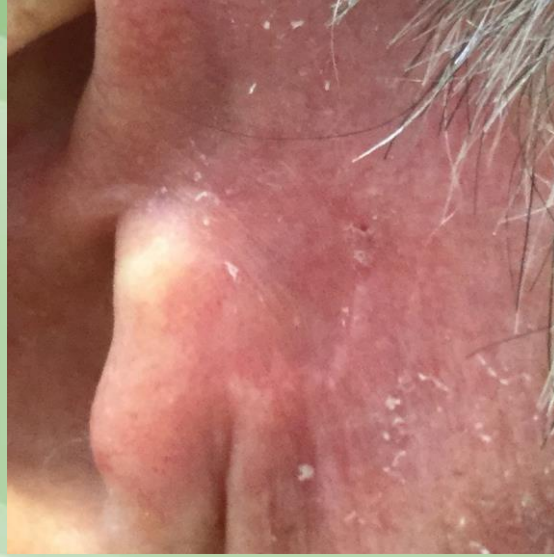

After

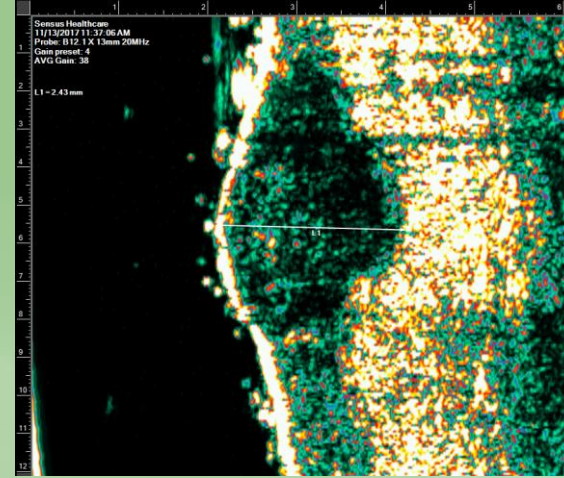
Cheek



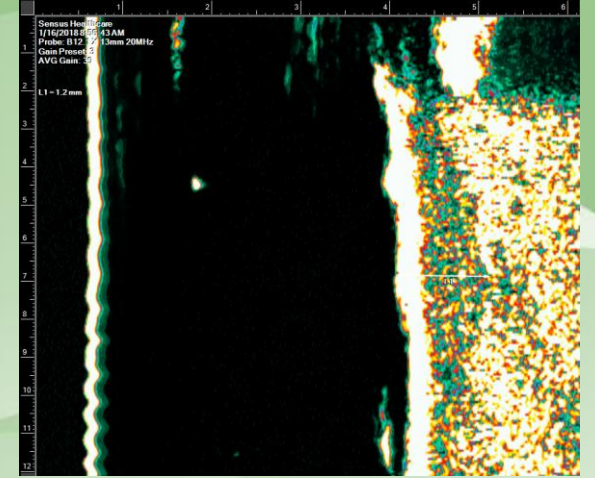
Before



After



Before



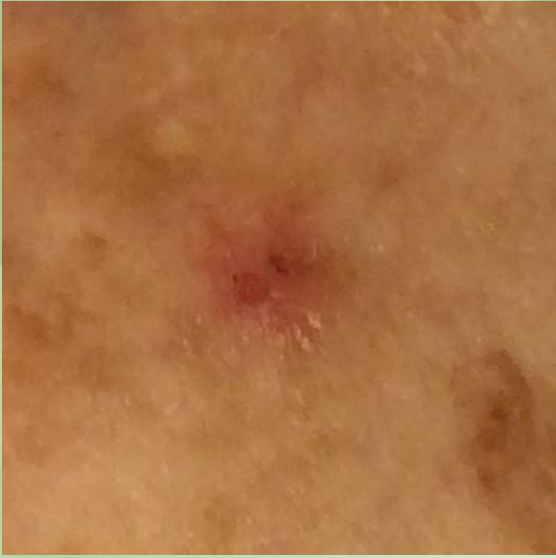After

Cancer type: Basal Cell Carcinoma, Nodular

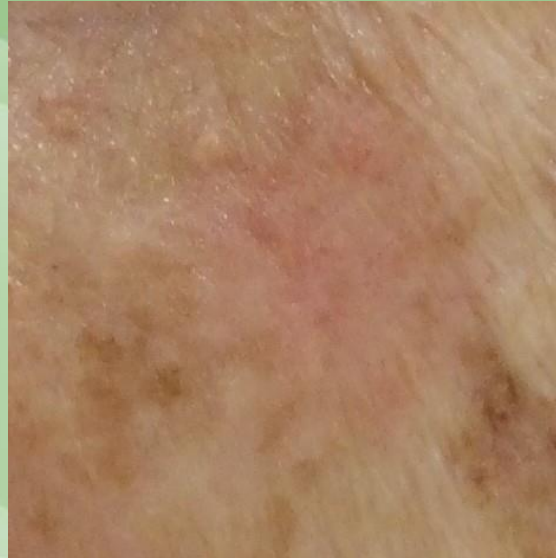Gender: Male

Age: 78

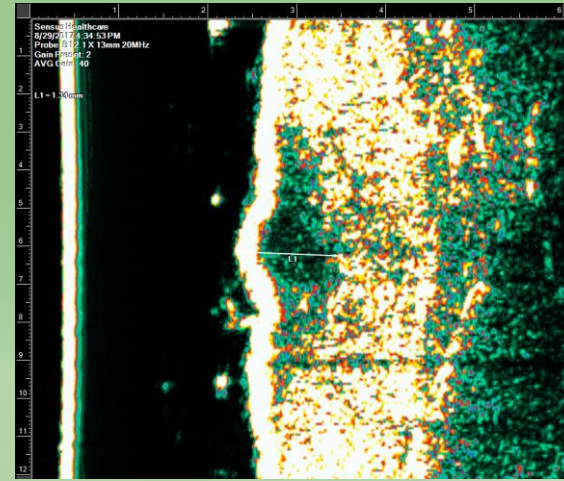
Chest



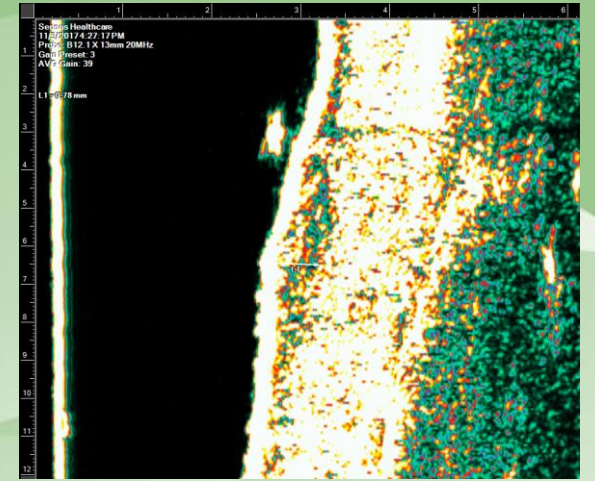
Before



After



Before



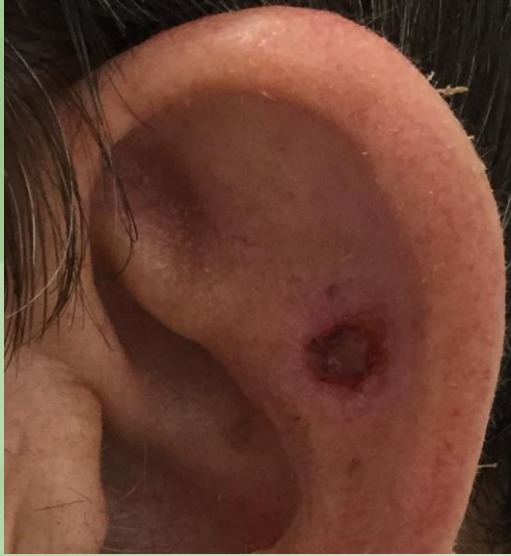After

Cancer type: Squamous Cell Carcinoma

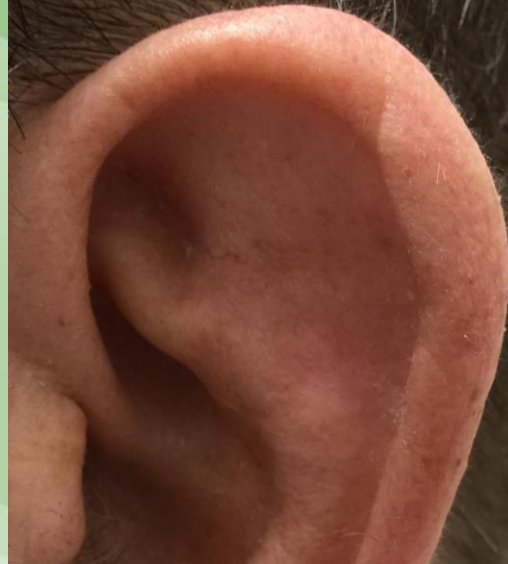Gender: Female

Age: 86

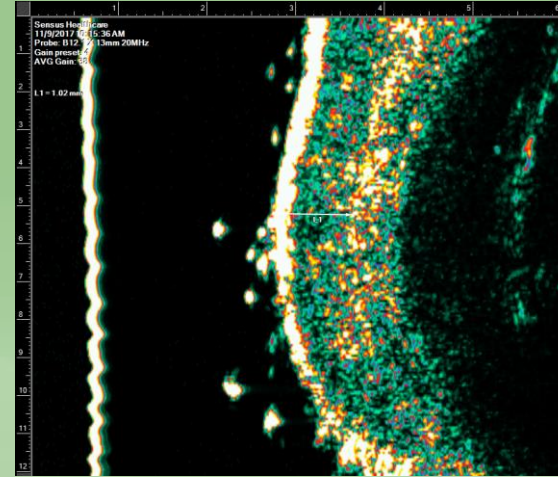
Ear



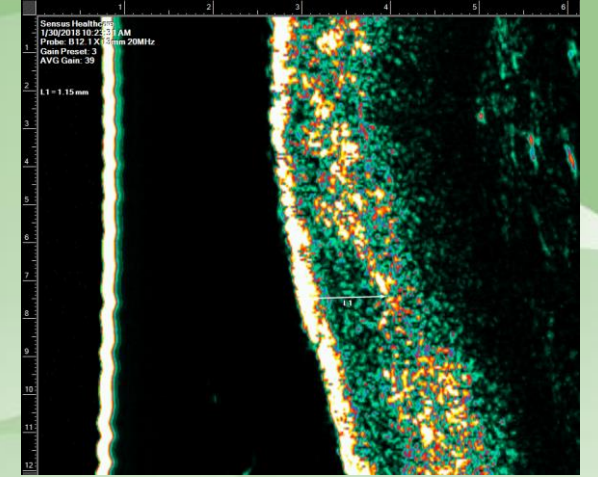
Before



After



Before



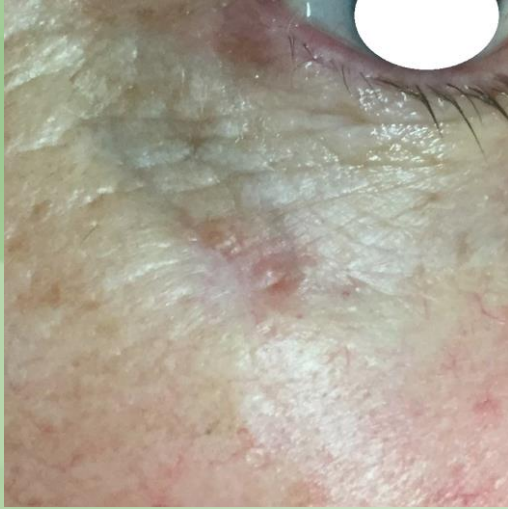After

Cancer type: Basal Cell Carcinoma, Infiltrative

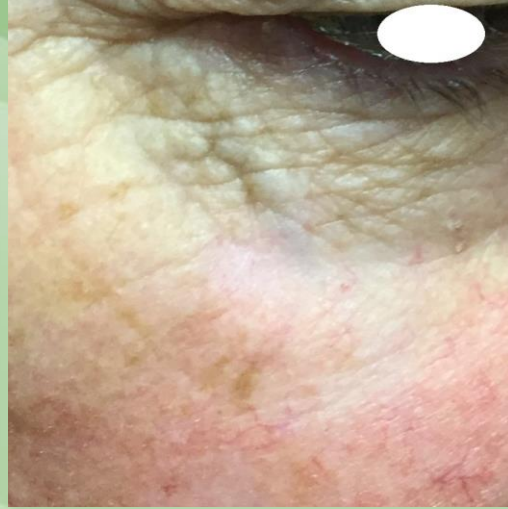Gender: Male

Age: 63

Eye Area



Before

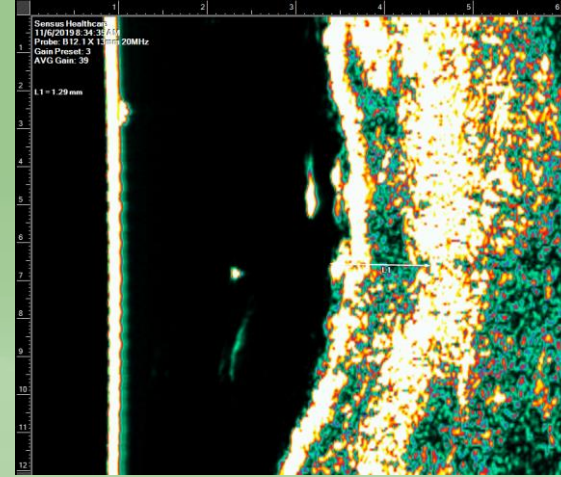


After

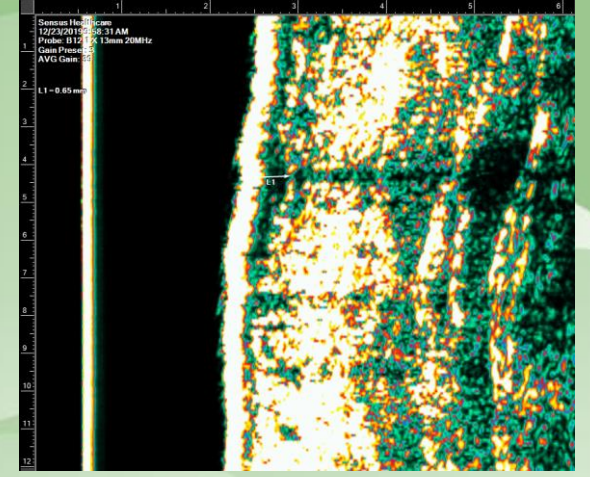
Cancer type: Basal Cell Carcinoma, Nodular

Gender: Male

Age: 71

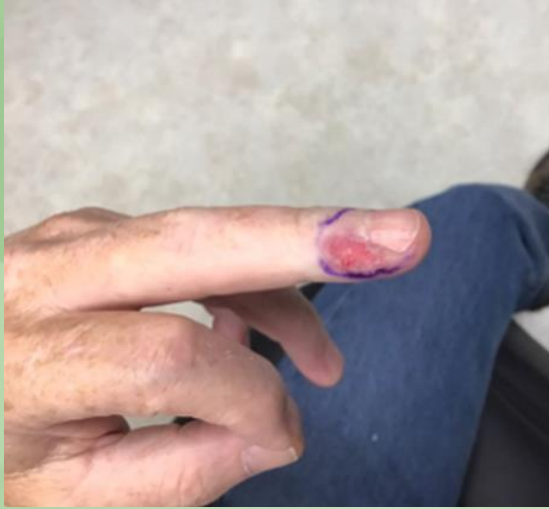

Before

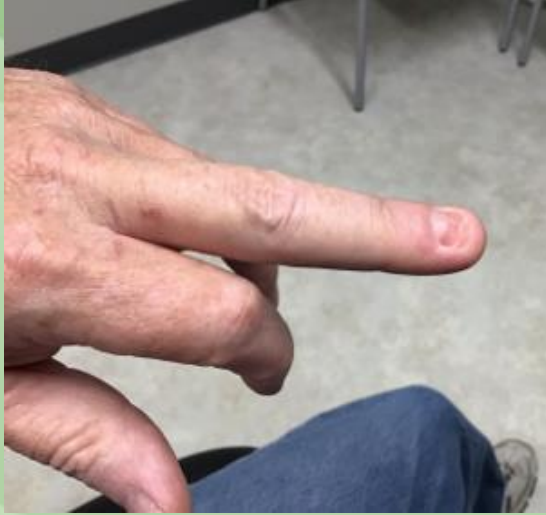

After

Finger



Before



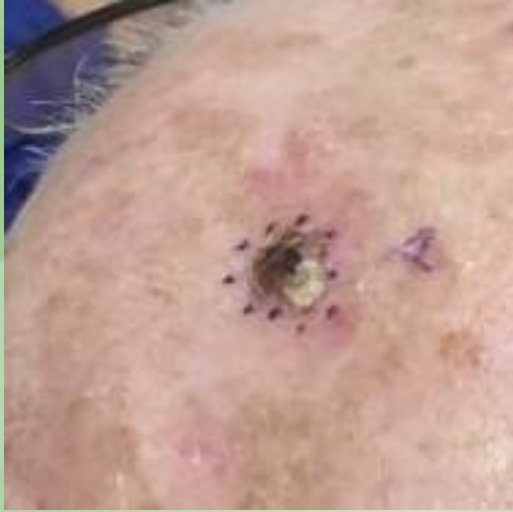After

Cancer type: Squamous Cell Carcinoma

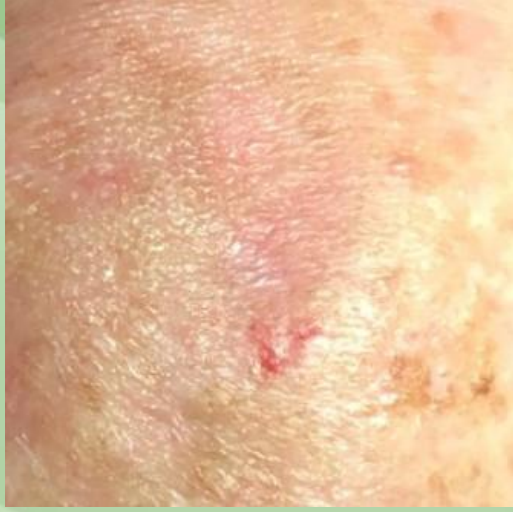Gender: Male

Age: 57

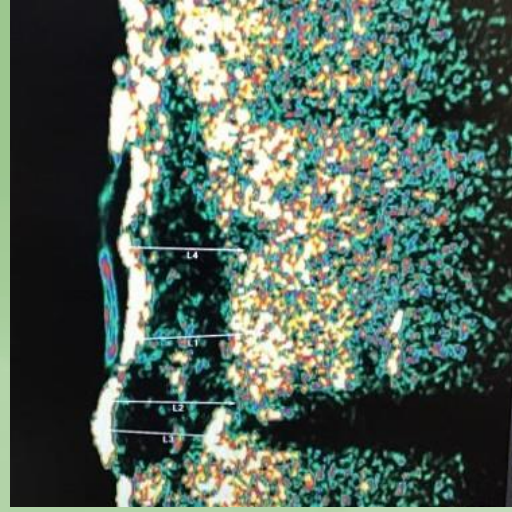
Forehead



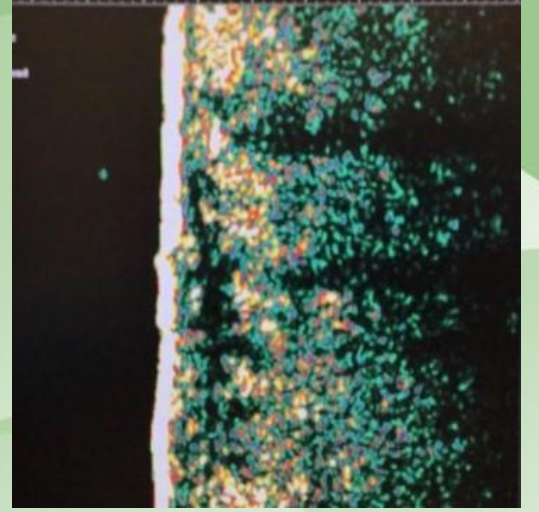
Before



After

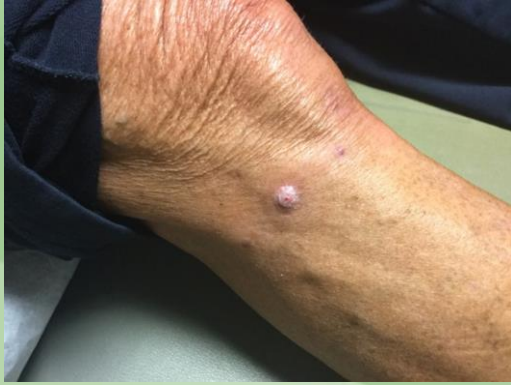

Before

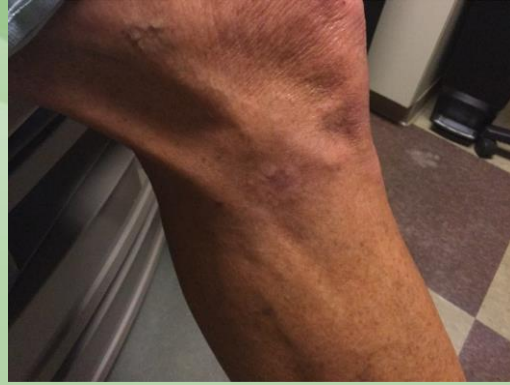

After

Knee

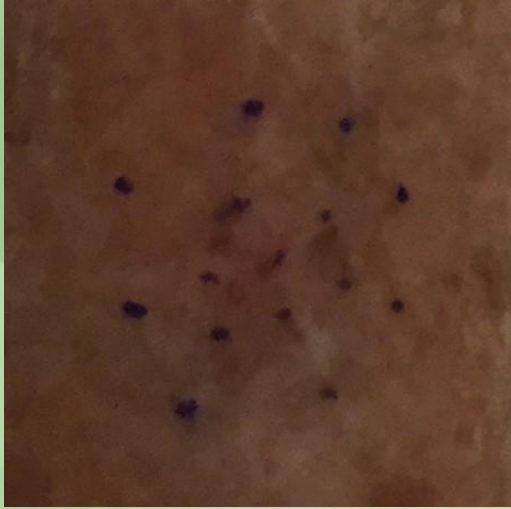

Before

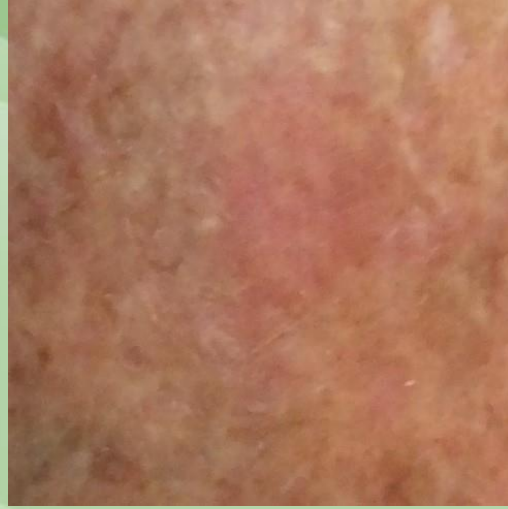

After

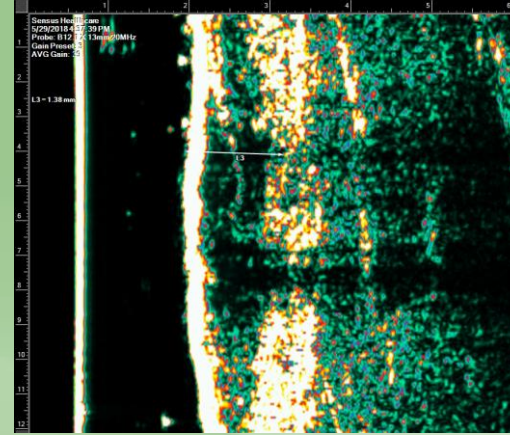
Leg



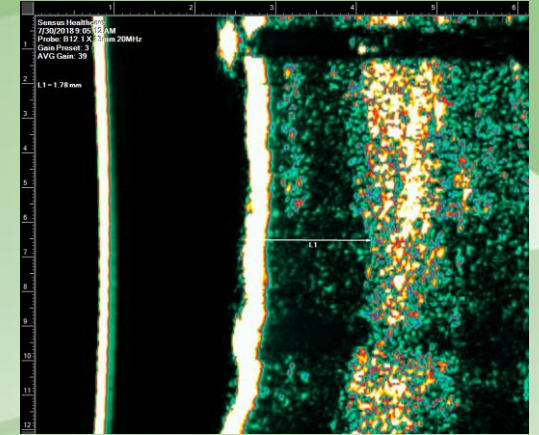
Before



After

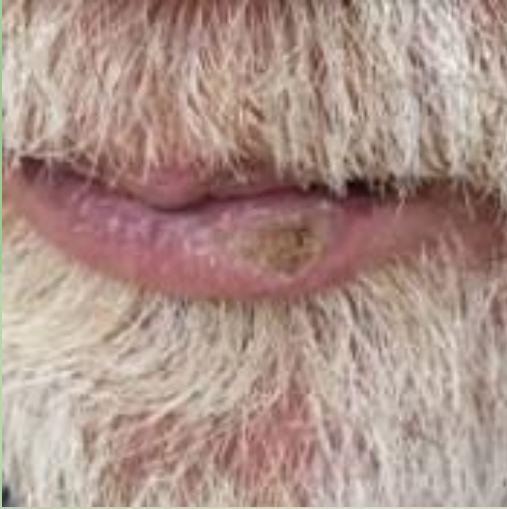

Before

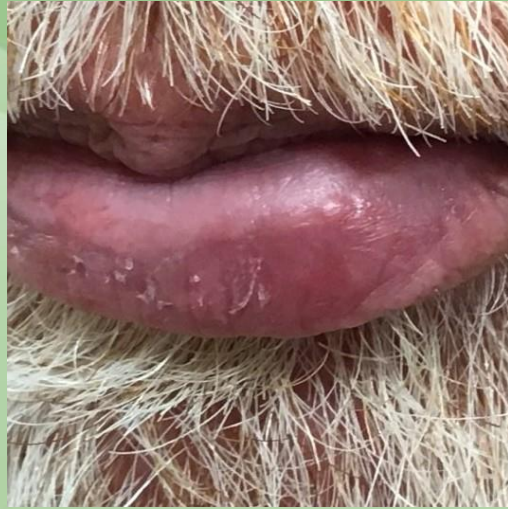

After

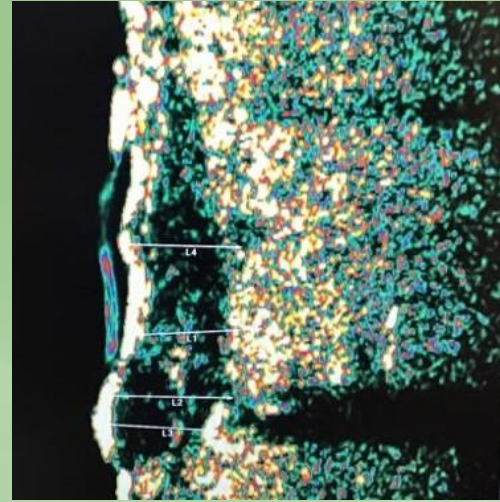
Lip



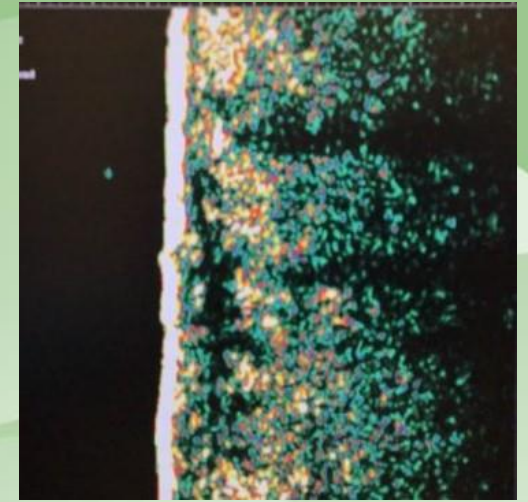
Before



After

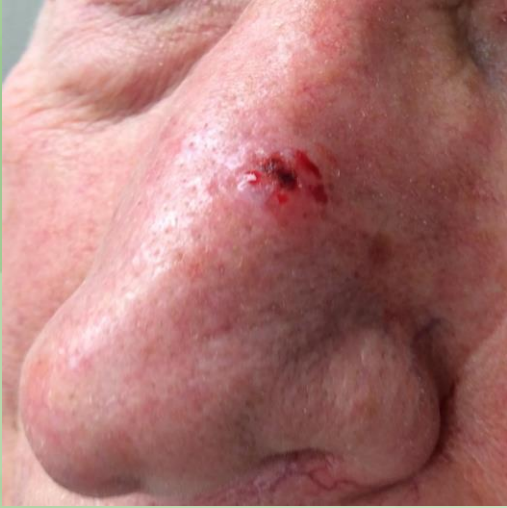

Before

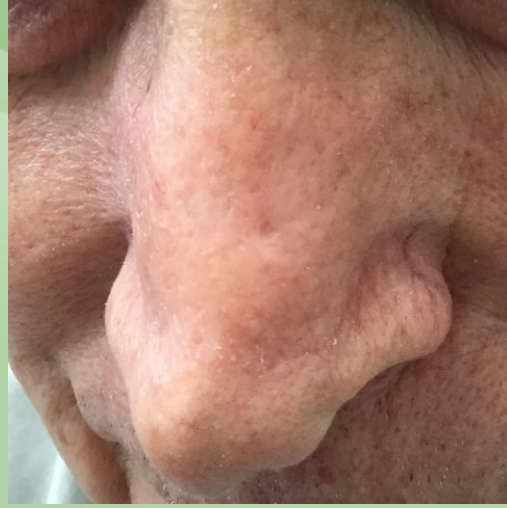

After

Nose



Before

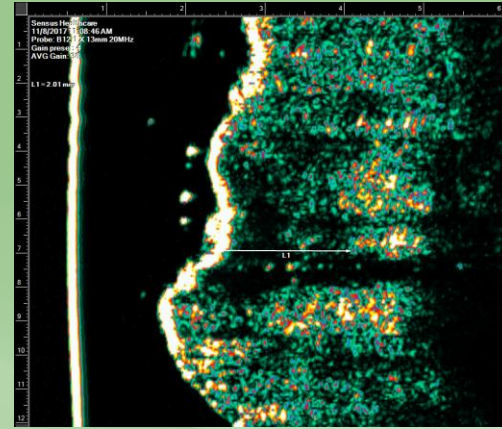


After

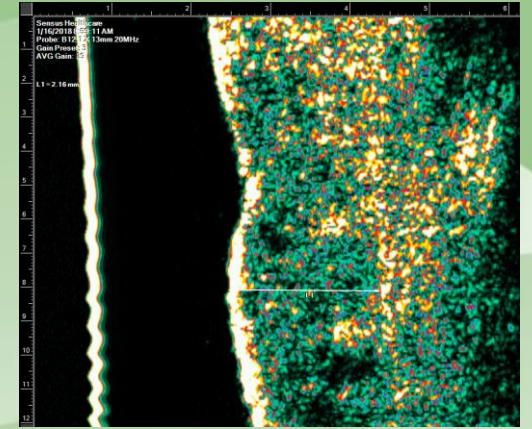
Cancer type: Basal Cell Carcinoma, Nodular

Gender: Male

Age: 78

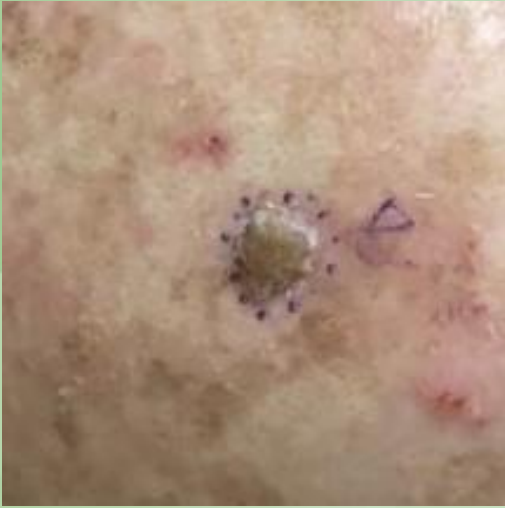

Before

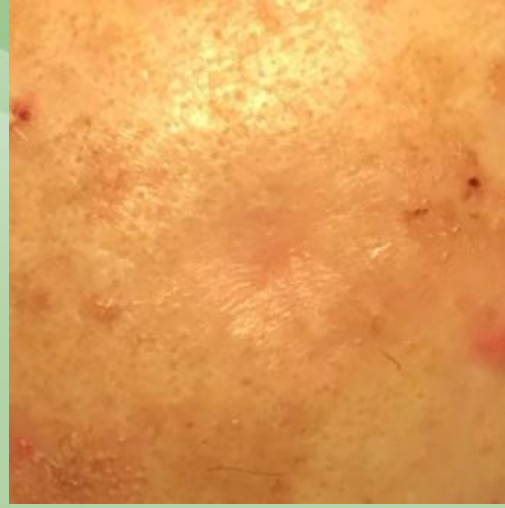

After

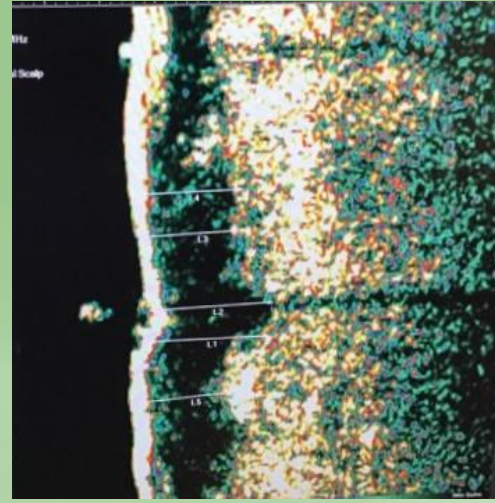
Scalp



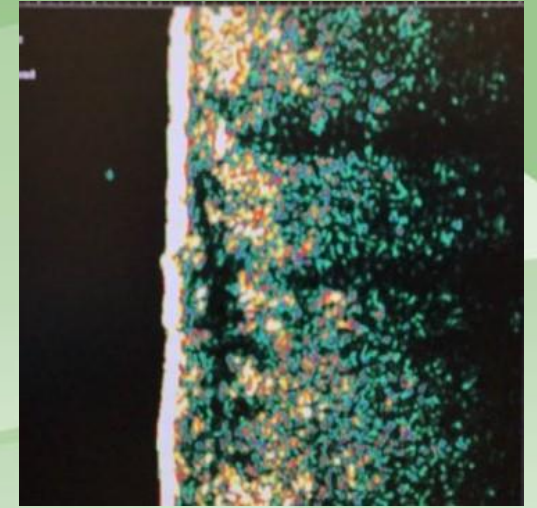
Before



After

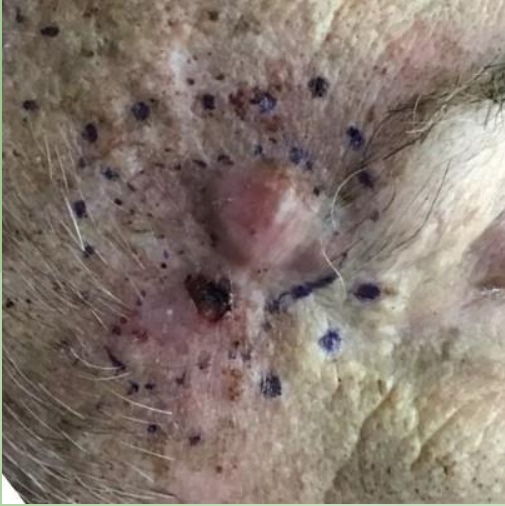

Before

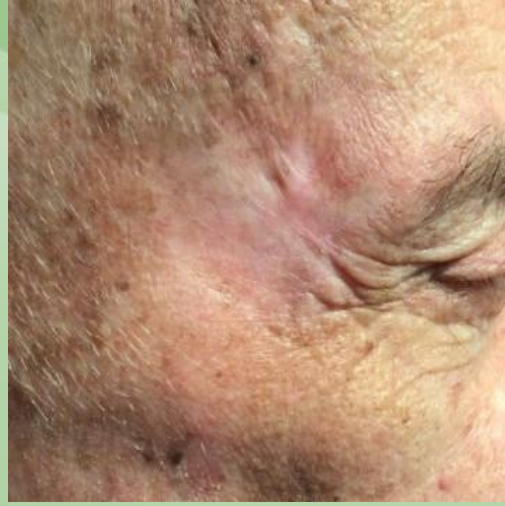

After

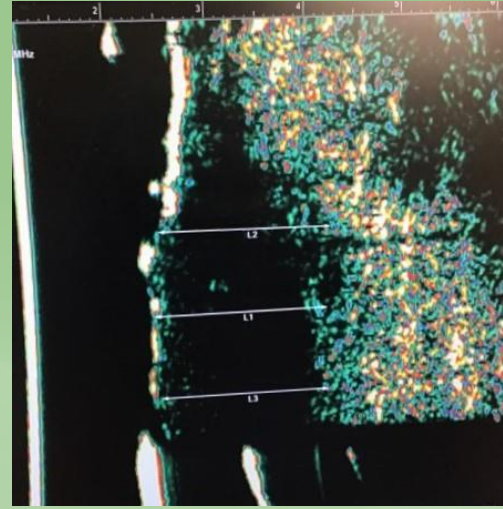
Temple



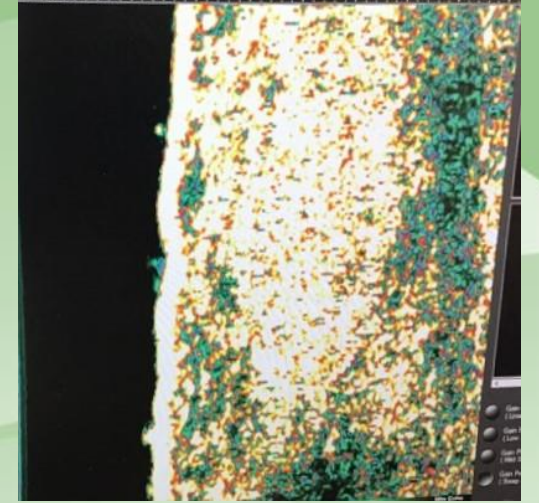
Before



After



Before



After